

Review Manuscript

STUDY OF VISCERA BY X-RAY CONTRAST MEDIA IN DIAGNOSTIC RADIOLOGY

¹PROF. DR. DHRUBO JYOTI SEN*, ¹MAULIK K. PRAJAPATI, ¹AVANI H. SHETH AND ²VIKRAMKUMAR V. PATEL

¹Department of Pharmaceutical and Medicinal Chemistry, Shri Sarvajanic Pharmacy College, Gujarat Technological University, Arvind Baug, Mehsana-384001, Gujarat, India, Phone: 00-91-2762-247711, Fax: 00-91-2762-247712, email: dhrubosen69@yahoo.com website: www.sspcmsn.org

²Department of Quality Assurance, S.K. Patel College of Pharmaceutical Education and Research, Ganpat University, Mehsana-Gozaria Highway, Kherva-382711, Ta. & Dist: Mehsana (N.G.)

Abstract : *The practice of clinical diagnostic radiology has been made possible by advances not only in diagnostic equipment and investigative techniques, but also in the contrast media that permit visualization of the details of the internal structure or organs that would not otherwise be demonstrable. The remarkably high tolerance of modern contrast media has been achieved through successive developments in chemical pharmacological technology. A single dose of X-ray contrast medium commonly contains upwards of 2000 times as much iodine as in the total physiological body content, and yet it is cleared from the system rapidly and naturally, usually with no adverse effects at all. The choice of contrast medium has always been a matter of debate, but is ultimately the responsibility of the radiologist. In order to be able to make a rational decision as to the selection of contrast media, it is necessary to have some understanding of the physical and physiological principles involved. The objective is to provide a background for non-specialists on this complicated specialist subject.*

Introduction:

How X-ray images are produced:

There are a number of ways in which energy is radiated or given off in the form of electromagnetic rays. These invisible rays are of the same general type and include heat, light, radio waves, X-rays and those given off by radioactive substances. The energy of the ray is related to its wavelength. Electromagnetic radiation that has a very long wavelength and low energy is radio waves, whilst a shorter wavelength and rather higher energy is light. The shortest wavelengths and highest energies belong to the X-ray region, and the very high energy levels involved give X-rays a property not by radiation of longer wavelength, which is the ability to pass through, or penetrate, materials.

**Correspondence : PROF. DR. DHRUBO JYOTI SEN, email: dhrubosen69@yahoo.com*

X-rays are produced when a beam of electrons, accelerated by a high voltage in a vacuum tube, collide with a heavy metal anode. As the X-ray beam passes through the patient, it undergoes a change. Some of the X-rays are scattered in different directions from the original beam, while others are absorbed by the body tissues: this latter process is known as attenuation. The quantity of X-rays removed varies according to the thickness of the patient and to the density of the particular organs involved. However, some of the X-rays pass right through the patient and remain in a beam emerging on the other side. The beam that emerges from the patient is different from the beam that went in.

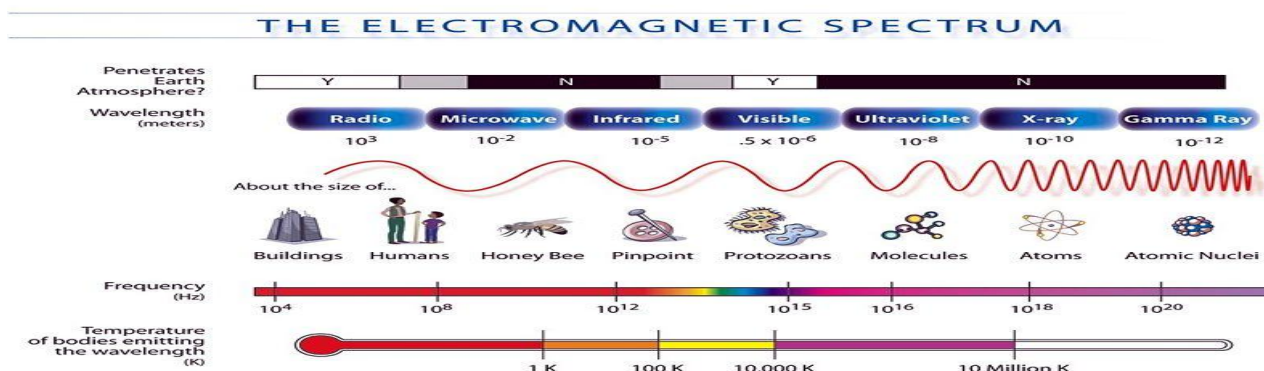


Fig. 1: The spectrum of electromagnetic radiation.

X-rays are produced when a beam of electrons, accelerated by a high voltage in a vacuum tube, collide with a heavy metal anode. As the X-ray beam passes through the patient, it undergoes a change. Some of the X-rays are scattered in different directions from the original beam, while others are absorbed by the body tissues: this latter process is known as attenuation. The quantity of X-rays removed varies according to the thickness of the patient and to the density of the particular organs involved. However, some of the X-rays pass right through the patient and remain in a beam emerging on the other side. The beam that emerges from the patient is different from the beam that went in. Not only it is less intense, but, because of the differential absorption by different tissues, the beam has a pattern of varying intensities across its cross-section: in other words, it has changed from a uniform beam into a beam that carries information. It is then displayed in such a way as to permit it to be visible by eye and a permanent record is usually made. Traditionally, the recording medium used is X-ray film (similar to ordinary photographic film), although for some years now, newer means of information recording, storage and display have been developed. These techniques, which are based on electronic detection, make computerized recording and viewing of digital images possible. These methods are used, for example, in digital radiography and digital vascular imaging, and a modification is used in computed tomography. Although the initial cost of such systems is high, the electronic storage is relatively cheap in comparison with X-ray films and contains much more information. Further advantages are gained from space saving and ease of access to the information. The greatest advantage, however, is the very rapid availability of the images and the ability to manipulate the data so as to make the images easier to interpret¹.

Why contrast media are necessary:

Different tissues within the body attenuate the beam of X-rays to different degrees. The degree of attenuation of an X-ray beam by an element is complex, but one of the major variables is the number of electrons in the path of the beam with which it can interact. The number of electrons in the path of the beam is dependent upon three factors:

- The thickness of the substance being studied
- Its density
- The number of electrons per atom of the element (which is equal to its atomic number)

In a complex mixture of elements, which is of course what we are concerned with in the organs of a patient, the degree of attenuation is particularly influenced by the average of the atomic numbers of all the atoms involved. Where there is a considerable difference between the densities of two organs, such as between the solid muscle of the heart and the air in the lungs, then the outlines of the structures can be visualized on a radiograph because of the natural contrast that exists. Similarly, if there is a difference between the average atomic numbers of two tissues, such as between soft tissues, which are composed of elements of low atomic number, and bone, which is partly composed of the element calcium, with a rather higher atomic number, then the outlines of the different structures can be seen by natural contrast. However, if the two organs have similar densities and similar average atomic numbers, then it is not possible to distinguish them on a radiograph, because no natural contrast exists. This situation commonly occurs in diagnostic radiography, so that, for example, it is not possible to identify blood vessels within an organ, or to demonstrate the internal structure of the kidney, without artificially altering one of the factors mentioned earlier. Two of the factors important in organ contrast can be artificially altered, the density of an organ, and, more usefully, the average atomic number of a structure. The

density of a hollow organ can be reduced by filling it with gas or air, providing negative contrast. This is mainly of historical significance, but is still used when, for example, gas is introduced into the stomach or colon during a double-contrast barium examination. The average atomic number of hollow structure such as a blood vessel can be increased by filling the cavity with a liquid of much higher average atomic number (such as iodine containing contrast medium) than that of blood. In fact this is the principle by which contrast media consist of solutions or suspensions of non-toxic substances that contain a significant proportion of elements of high atomic number, usually iodine².

How are contrast media used?

There are numerous radiological examinations that involve the use of contrast media. A few of the most common are described below. It should be noted that the volume, strength, as well as the type of contrast medium, will vary between patients according to the examination type and radiologist's requirements.

1. Angiography
2. Intravenous urography (IVU), intravenous pyelography (IVP)
3. Computed tomography (CT)
4. Myelography
5. Interventional techniques
6. Other examinations

Angiography

Angiography is the general term which describes the investigation of blood vessels. Usually a distinction between arteriography and venography is made, depending on the kind of blood vessel (artery or vein) which is examined.

Arteriography

In arteriography a contrast medium is introduced via a catheter into an artery, which makes the lumen of that vessel opaque to X-rays. The natural flow of blood carries the contrast medium peripherally, and by taking a series of radiographs the radiologist can obtain images to get a road map of the blood supply to an organ, or a limb. Localized narrowing or obstruction of an artery or a pathological circulation in a tumor can then be identified. Sometimes the radiologist may then proceed to treat the patient using the catheter system, which was introduced initially for diagnosis. Arteriography is relatively time consuming for the radiologist

depending on the complexity, ½ hour – 2 hours, or even longer can be spent on the procedure.

Venography (phlebography)

The natural flow of blood in veins is towards the heart, and by injection of a contrast medium into a peripheral vein, a map of the venous drainage of a limb can be obtained. The larger size and greater number of peripheral veins, and the fact that the flow of blood is much slower in veins than in arteries, means that it is usual for the radiologist to take several radiographs of each area with the limb in different positions. The commonest indication for venography is to confirm a suspected diagnosis of deep venous thrombosis of the leg. Venography is also performed on organs within the body by introducing a catheter into a peripheral vein and manipulating it into an organ.

Digital subtraction angiography (DSA)

A special type of angiography is digital subtraction angiography (DSA). These procedures involve the use of specialized electronic equipment, computing and radiographic hardware to produce rapid sequential images. The DSA image is produced by electronically subtracting images without contrast media from images after contrast media injection. The result of this subtraction process is the visualization of contrast filled vessels which are free from the distraction of overlying structures.

Intravenous urography (IVU), intravenous pyelography (IVP)

When injected intravenously, most contrast media are rapidly excreted by the kidneys, and a series of radiographs taken after the injection will demonstrate the urinary tract. Intravenous urography is still the basic radiological examination of the urinary tract. The main indication is to assess the morphology of the kidneys. Further indications are: detection of kidney stones and calcifications in the ureter or bladder, assessment of obstructed urinary flow and investigation of patients with haematuria (the passage of blood in urine). Children may be investigated for congenital abnormalities of the urinary tract. In recent years for some investigations of the urinary tract, particularly uncomplicated infection, an ultrasound examination and plain abdominal radiograph have replaced intravenous urography as the initial investigation of the urinary tract.

Computed tomography (CT)

Since 1973 an imaging technique known as computed tomography (CT) has developed to become one of the most important radiological examinations in the

industrialized countries. CT uses conventional X-rays in a thin nondivergent beam to produce cross sectional images of the body. The X-ray tube and an array of detectors mounted within a supporting framework, rotate round the patient with each scan. CT produces digitalized images, although these are usually printed onto hard copy film in a format that is useful for transfer and viewing throughout the hospital. By electronic means CT improves via higher contrast sensitivity, the natural radiological contrast between organs. However, it cannot create contrast where none exists naturally. CT is exceptionally sensitive to contrast media and can detect abnormalities, caused by disease, following an injection of an intravenous dose of contrast medium. This procedure is known as "enhancing" the scan. About 43% of all CT procedures involve the use of a contrast medium. CT is widely used throughout the body but the most frequently investigated areas using this technique are neuroradiology (brain and lumbar spine) and general radiology of the chest, abdomen and pelvis. It is particularly useful for the diagnosis, staging and follow up of malignant disease.

Myelography

The spinal cord and the attendant nerve-roots which radiate from it cannot be visualised using conventional X-rays alone without the use of contrast media. They can be visualized directly using magnetic resonance imaging (MRI). They can be visualised if contrast medium is injected in the cerebrospinal fluid (CSF), which surrounds the spinal cord, rendering the CSF radio-opaque but not the cord or nerve roots. Specific contrast media have been developed for this examination. The majority of myelograms (or radiculograms) were performed to examine the lumbar region to confirm the clinical suspicion of a prolapsed intervertebral disc. However, CT and MRI have now largely replaced myelography as the initial investigation of the lumbar spine. Myelography, particularly combined with CT scanning is still used however to investigate the cord and cervical region and its nerve roots in difficult cases when other investigations are equivocal or normal.

Interventional techniques

Many radiologists are now specialized in therapeutic procedures that have been developed from radiological diagnostic techniques using catheters and guidewires. These procedures include:

- The dilation of pathologically narrowed arteries - angioplasty, percutaneous transluminal angioplasty (PTA).
- The deliberate occlusion of arteries supplying abnormal areas such as tumours, aneurysms and vascular malformations, so depriving them of their blood supply.

- The placement of artificial tubes or stents into blood vessels, bile ducts or ureters to bypass a pathological narrowing.

These procedures often necessitate the use of high doses of contrast medium, because several examinations of the same vessels may be required during the control of the therapeutic process.

Other examinations

There are a wide variety of other examinations where contrast media are used. For example, contrast medium may be introduced into structures such as joints to study the anatomy and pathology (arthrography) or into the duct systems of various glands, such as the salivary glands (sialography). It may be used to examine the pancreatic/biliary duct system (retrograde cholecystopancreatography), to ascertain the cause of an obstruction to the ducts, or directly into the bladder to determine whether it refluxes back into the ureter during voiding (micturating cystography). In addition, dilute iodine containing contrast media when given orally or rectally can be used to identify organs such as the small bowel (oral use) or the rectum (rectal use) during CT scanning. A suspension of barium sulphate in water is widely used to examine the stomach (barium meal) small intestine (small bowel exam or enema) or colon (enema). Air, or where available, carbon dioxide is used as a negative contrast agent to distend the bowel and provide additional contrast³.

What types of contrast media are there?

There are numerous types of contrast media which have different applications, depending on their differing chemical and physical properties. Radiological contrast media are usually water soluble solutions, but there is one commonly used variety that is based on a suspension of large insoluble particles. This is the barium sulphate mixture that is used for barium meal and barium enema examinations of the upper and lower gastrointestinal tracts. Barium sulphate suspensions have better coating properties than the iodinated contrast media, and tend to form thin layers spread over the lining of the gut. However, if barium sulphate escapes from the gut into the peritoneal cavity, which may occur if there is a perforation of the bowel, it is irritant to the delicate peritoneal membrane, and may cause a chemical peritonitis. Therefore, when a perforation of the bowel is suspected, examination of the gastrointestinal tract with a water-soluble iodinated oral contrast medium is more appropriate. If, however, there is a risk of aspiration of contrast medium into the lungs, high osmolar (ionic) contrast media should not be used because they can cause water logging of the lungs (pulmonary oedema). All of the other X-ray contrast¹⁷⁴

media are based on the element iodine. Many elements have higher atomic numbers, but no others have the chemical characteristics that make iodine able to form soluble compounds with low toxicity. It is these latter properties which make iodine-containing contrast media suitable for radiography. Certain iodine-based contrast media have a molecular structure that makes them particularly suitable for the examination of the biliary tract. Agents that can be taken orally, such as calcium iopodate, are excreted by the liver, concentrated in the gall-bladder and will normally opacify it after a few hours. This examination is termed an oral cholecystogram, and is performed in cases of suspected gallstones. A drink or a meal containing a substantial quantity of stimulating agent like fat or chocolate given at the end of the examination causes the gall-bladder to contract and expel the concentrated contrast medium into the biliary ducts. However, patients who have had their gall-bladders removed, and so cannot concentrate a contrast medium within the biliary tract, require intravenous cholegraphic media, such as meglumine iotroxate, which are sufficiently concentrated when excreted by the liver to yield satisfactory films when they enter the biliary tract. All other iodinated contrast media, i.e. approximately 90% of all contrast media used in X-ray imaging, are loosely termed 'intravascular' or 'general' contrast media. They can be classified into ionic and nonionic media, or alternatively into high-osmolar, low-osmolar and iso-osmolar (relative to blood) contrast media⁴.

All contrast media are not the same:

Contrary to some beliefs, there are major differences between the general contrast media, not only whether they are ionic or non-ionic relative to blood, but also between non-ionic molecules, which differ in many other parameters (e.g. viscosity, osmolality, chemotoxicity, hydrophilicity, histamine-releasing potential).

Viscosity, Osmolality, Chemotoxicity, LD50

Viscosity

The viscosity of a liquid is assessed by measuring its rate of flow through a standard thin capillary tube under standard conditions of pressure and temperature. The practical importance of viscosity of a contrast medium relates chiefly to the force that is required to inject it through a needle or catheter into a patient, which limits the rate at which it can be injected. This is particularly so when the radiologist is using long and thin injection-catheters that are necessary for certain arteriograms and interventional procedures, the slow flow of a viscous contrast medium may lead to inadequate visualization of a vessel. Of course, the viscosity can be reduced by lowering the concentration of the contrast medium, but reducing the iodine concentration in this way

may also result in unsatisfactory opacification. Since viscosity is inversely related to temperature, warming the contrast medium may partly resolve this problem, but the inconvenience of only being able to use the contrast medium at its maximum effect immediately after it has been warmed has also to be considered. Using a mechanical pump to inject the contrast medium helps, but high injection-pressures may lead to unacceptable stress on catheters, connecting-tubes or connectors, and so necessitate stronger, more expensive, equipment⁵.

Osmolality

All biological membranes have the property known as semi-permeability, which is the ability to allow water and other small molecules to pass freely through them, but not to allow the passage of large molecules in solution in the water. Since water can pass freely in both directions, but large, dissolved molecules cannot, water gradually passes from a weak solution on one side of a semi-permeable membrane into a stronger solution on the other side. The higher concentration solution can be said to 'draw' water from the lower concentration solution. This process is called osmosis, and the force exerted is called osmotic pressure. Osmotic pressure is determined solely by the concentration of dissolved particles. Note that this is not necessarily the same as the concentration of dissolved molecules, because a single molecule, when it dissolves, may give rise to more than one particle in solution, by dissociating to form ions. For example, sodium chloride dissociates into a sodium ion and a chloride ion in solution. $\text{NaCl} \rightarrow \text{Na}^+ + \text{Cl}^-$

This process has an important bearing on the tolerance of contrast media, since, in general, the higher the osmotic pressure the poorer the tolerance. Ionic contrast media undergo this dissociation, whilst newer, non-ionic contrast media do not. The osmotic pressure of a solution - its osmolality - being simply a function of the concentration of particles within it, can be expressed in terms of its concentration of particles (osmoles) per unit weight (kilograms) of solvent, or as is more usual in medicine, in milliosmoles per kilogram of water (mOsm/kg H₂O). The closer the osmolality of radiological contrast media is to that of body fluids the better the general tolerance. The osmolality of blood, and of the cerebrospinal fluid, which surrounds the brain and spinal cord, is about 290mOsm/kg. Almost all of the currently available ionic, non-ionic monomeric and ionic dimeric contrast media have osmolalities in excess of this figure, though some are very much higher than others (see Fig. 2). Osmolality is directly responsible for a number of clinically important effects. The sensations of heat and discomfort or even pain that many patients experience when undergoing arteriography with some contrast media¹⁷⁵

are directly related to the osmolality. Other clinically significant effects that can be attributed to the osmolality problem include damage to the blood-brain barrier, renal damage and disturbance or electrolyte balance in small children. Both the viscosity of a contrast medium and its osmolality are related to the concentration of the contrast medium, usually referred to as its strength. The strength of a contrast medium is usually given as its concentration in iodine, a figure after the brand name, indicating the concentration in milligrams of iodine per millilitre. With increasing strength of contrast medium, the opacifying power of the solution increases, but so, of course, do the osmolality and viscosity, while tolerance tends to decline. These considerations make it necessary to have several different strengths and presentations of each contrast medium⁶.

Chemotoxicity

The term 'chemotoxicity' refers to the mechanism responsible for causing the toxic effects of contrast media that cannot be explained by other means (e.g. osmolality, electrical charge). There are a number of properties of contrast media that relate to this term (e.g. hydrophilicity/lipophilicity, protein-binding, histamine release). The hydrophilicity of a contrast medium is its preference for aqueous solvents, whereas its lipophilicity refers to its preference for fat-like (lipid) organic

solvents such as the chemical solvent n-butanol. Since n-butanol does not mix with water, it is possible to assess the relative degree of lipophilicity by adding equal parts of water and n-butanol to a small quantity of contrast medium and shaking the mixture well, after which the solvents are allowed to separate into two layers and the amount of contrast medium dissolved in each layer is measured. The ratio of the amount in the lipid layer to the amount in the aqueous layer is termed the partition coefficient, which is therefore high for compounds of high lipophilicity and low for compounds of lower lipophilicity. Lipophilicity has been found to correlate roughly with the toxicity of ionic contrast media. Non-ionic contrast media seem to be too hydrophilic to make differences in the partition coefficient a critical issue. In this case properties other than lipophilicity (e.g. hydrogen bonding) are responsible for interactions with biological molecules and membranes. Protein-binding refers to the percentage of contrast medium which becomes bound to the plasma proteins in the blood stream. The cholegraphic media discussed in the previous chapter derive their ability to be excreted and concentrated in the bile, rather than to be rapidly eliminated by the kidneys, from their very high degree of protein-binding. In line with the above hypothesis, the cholegraphic agents (which are also ionic) have a rather higher chemotoxicity than the urographic contrast med

Type	Composition w/v%	Iodine mg/ml	Osmolality mOsmols/kg	Viscosity Cps at 37°C
High osmolar ionic monomer	Sodium iothalamate 54%	325	1843	2.75
	Meglumine diatrizoate 65%	306	1530	5.0
Low osmolar ionic dimer	Meglumine ioxaglate 39.3%	320	580	7.5
	Sodium ioxaglate 19.65%	322	590	7.3
Non-ionic monomer	Iopamidol 61.2%	300	616	4.7
	Iohexol 64.6%	300	640	6.3
	Ioversol 63.6%	300	645	5.5
	Iopromide 62.3%	300	610	4.6
Non-ionic dimer	Iotrolan 64.1%	300	320	8.1
	Iodixanol 65.2%	320	290	11.4

Table 1: Comparative Data on X-Ray Contrast Media in the United Kingdom

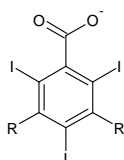
Histamine release is a characteristic of allergic reactions. A possible model for the contrast media to cause allergy-like reactions is their property of releasing histamine from mast cells. Experimentally, it is expressed as a percentage of the total histamine content of the cells. LD50 Until recently a frequently quoted figure as a speculative basis for comparison of contrast media toxicity has been the LD50. This is the amount of contrast medium (usually expressed in the form of gms iodine/kg of the animal's weight) that will kill 50% of a group of treated animals. Since the iodine containing contrast media are normally well tolerated, the LD50 value for this substance group is correspondingly high. Modern contrast agents, because of their more physiological properties have higher LD50. The lowest LD50 data published for various non-ionic contrast media are greater than 21g iodine/kg (mice), which exceeds the maximal anticipated clinical dose in humans by at least tenfold. Determination of the LD50 has not proved to be particularly helpful for risk estimation of contrast media intended for use in humans. LD50 results do not correlate well with mortality and morbidity rates in man, probably for two reasons. Firstly, because there is always considerable inter-species variation, and secondly because these results refer to poisoning of animals by doses high enough to reflect solely osmotoxic effects, whereas deaths when they occur in humans are idiosyncratic and not usually related to osmotic effects. Instead, an acute toxicity test without determination of an "exact LD50 value" is carried out. The objective of this test is to determine the profile of toxic action and the tolerance

threshold of a substance following single application. The advantage of this procedure is that it requires considerably lower numbers of animals and helps to establish the more clinically relevant "no effect level"⁸.

Ionic and non-ionic media:

In order to appreciate the relative merits of the current varieties of contrast media, it is useful to review why and how they were first developed. It was the custom in the early 1920s to treat syphilis with high doses of sodium iodide. The urine in the bladder was observed to become radio-opaque during this treatment, and further studies showed that the iodine content was responsible. Sodium iodide was too toxic for satisfactory intravenous use, and so the search was on for a less toxic iodinated compound. The first suitable structure was a derivative of the chemical ring structure called pyridine, to which a single iodine atom could be bound in order to render it radio-opaque. The first radiological contrast medium that could produce safe and reliable intravenous urograms in patients was Uroselectan. Uroselectan contained two parts, a large negatively-charged iodinated ion (the anion), and a much smaller positively-charged sodium ion (the cation), so that when it is dissolved in water it gives rise to two particles for each molecule of contrast medium. Therefore it was an ionic contrast medium, and it had a high osmolality. Within a few years, similar compounds were synthesized which had two atoms of iodine each, thus doubling the radio-opacity for the same contrast media concentration⁹.

Structure	Class	Examples of media	Iodine atoms to particles ratio	Approx. No. of times more osmolar than blood at 300 mg l/m
R=Various organic chains				
1. Ionic monomer	Ionic monomer	Iothalamate	3 : 2	5
(Na+ or Megl+)		Diatrizoate		



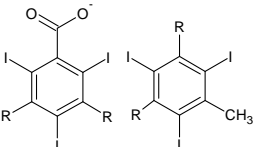
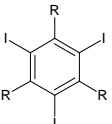
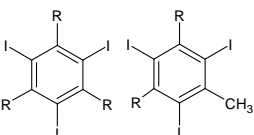
2. Ionic dimer	Ionic dimer	Ioxaglate	6 : 2	2
(Na+ or Megl+)	(low osmolar ionic)		or	
			3 : 1	
3. Non-ionic monomer	Non-ionic monomer	Iopromide	3 : 1	2
	(low osmolar non-ionic)	Iopamidol		
		Iohexol		
		Iopentol		
		Ioversol		
4. Non-ionic dimer	Non-ionic dimer	Iotrolan	6 : 1	2
		Iodixanol		Iso-osmolar

Table 2: Comparison of the structure of the ionic and non-ionic X-ray contrast media. Note that the osmolality of different contrast media within the same group may be somewhat different.

In the 1950s, contrast media were developed that were based on the six-carbon benzoic acid ring rather than the five-carbon pyridine ring. This structure was able to carry three atoms of iodine, and therefore was even more radio-opaque. However, each molecule still dissociated into two particles on dissolving, because they were ionic media, and therefore they still had a very high osmolality. All currently used ionic contrast media have meglumine cations, or sodium cations, or a mixture of both. Meglumine is an organic cation chosen because of its lower pharmacological activity than that of the sodium ion (and therefore better tolerance), but being a much larger ion, meglumine produces a medium of much higher viscosity. Meglumine is also diuretic. Since ionic contrast media have high osmolality, which is associated with unwanted side effects, a search was undertaken in the 1960s and 1970s for ways of reducing osmolality, whilst maintaining satisfactory radio-opacity. Two methods were found whereby this could be achieved. One method of reducing osmolality was to join two contrast medium molecules together, producing a much larger molecule, which still ionizes, but possesses six atoms of iodine per molecule.

This type of contrast medium is termed an ionic dimer, or low-osmolar ionic contrast medium. The only such contrast medium available is ioxaglate.

The other method was to replace the dissociating cationic portion of the contrast medium molecule completely with a non-dissociating organic chain. Since such a substance does not ionize, it is termed a non-ionic medium. The first non-ionic contrast medium, metrizamide, became available in 1975. It revolutionised the practice of contrast radiology. However, metrizamide is of low thermal stability and cannot be autoclaved, and so has to be supplied as a freeze-dried powder with a separate solvent. It was succeeded by the second generation of non-ionic contrast media in the early 1980s. These are iopamidol, iohexol, iopromide and more recently ioversol and iopentol. One might imagine that the osmolality of a non-ionic contrast medium would be exactly half of that of an ionic contrast medium of the same iodine concentration, but in fact, it is even lower, owing to the association of particles in solution. The points discussed above are illustrated in Fig. 3. It can be seen that while all non-ionic contrast media may be termed 'low-osmolar', the

term includes not only the non-ionic contrast media but also the ionic dimer ioxaglate. However, ioxaglate shows some inferior features compared to the non-ionic media: for example its relatively high protein-binding. The well known toxic effects caused by its electrical charge and its relatively high viscosity. Further developments resulted in dimeric non-ionic contrast media, which are virtually isotonic to blood and cerebrospinal fluid. Currently only two compounds iotrolan and iodixanol are available (see Fig. 3)¹⁰.

Safety of contrast media:

Contrast media are among the safest of all of the pharmaceutical products available to the doctor today. They are anomalous in that they are not intended to have therapeutic activity: indeed, the ideal contrast medium would have no pharmacological activity at all. For this reason the concept of therapeutic ration, which can be applied to medicines, does not apply to contrast media. The development of a contrast medium from the first design of the molecule through to product licence takes many years. The minimum period of time that can reasonably be allotted to preclinical and clinical development is six years, and in practice it is not uncommon to take nine years or even more. During this long period, the tolerance of the medium is rigorously tested by collecting data from various preclinical and clinical trials to establish a profile for the product. One critical area examined during its development is the incidence of adverse reactions. The rate of adverse reactions to iodinated contrast media on the market is extremely low, but such reactions do occur - just as they do with every pharmaceutical product. The adverse reactions associated with contrast media can be divided into two groups: Those reactions that are clearly dependent on the dose and concentration of the contrast medium administered and those that are almost independent of dose and concentration. Dose-dependent adverse reactions are mostly due to the physiochemical effects of the contrast medium, such as its osmolality, or electrical charge. Possible adverse reactions include heat, pain, vasodilatation, cardiac depression and hypotension. The adverse reactions which are almost independent of dose and concentration are nausea and vomiting as well as allergy-like or hypersensitive reactions such as urticaria (hives), certain cardiovascular reactions, bronchospasm and laryngospasm, but there is little evidence of any antigen-antibody interaction. These reactions cannot be predicted and their underlying cause remains unknown.

For clinical purposes it is meaningful to divide contrast media reactions into three categories:

1. Minor e.g. Flushing, nausea, vomiting, pruritis, mild rash, arm pain
2. Moderate e.g. More severe urticaria, facial oedema, hypotension, bronchospasm
3. Severe e.g. Hypotensive shock, laryngeal oedema, convulsions, respiratory and cardiac arrest

Most contrast media reactions are minor and need no treatment. Moderate reactions are encountered rarely (about 1%) and severe reactions very rarely (about 0.1%), but all moderate and severe reactions require adequate treatment. Deaths following contrast media administration are extremely rare. Reported mortality rates vary between 1 in 10,000 and 1 in 169,000 averaging around 1 in 75,000. Katayama et al. (Radiology 1990; 175: 621-628) found that there is a reduction in adverse reaction rate of about four times using low osmolar contrast media (LOCM) for intravenous injection compared to high osmolar contrast media (HOCM). There is surprisingly no documented difference in mortality between intravenous LOCM and HOCM in large series from Japan and Australia. It is not usually possible to predict severe reactions, even by looking at the effect of a small "test dose" of a contrast medium. Guidelines have been produced for the use of low osmolar contrast agents¹¹.

Choice of contrast medium:

A radiologist will use his/her clinical experience and judgement to decide which contrast medium should be used in a particular situation. In reaching his/her decision whether to use LOCM or HOCM, a nonionic medium or an ionic medium he/she will consider many factors including clinical factors and cost. To help the decision The Royal College of Radiologists has published a list of guidelines. They are based on the concept of the high-risk patient: that is, a patient in whom the risk of severe reactions is increased over that of normal population. This group includes:

- Infants (introduction of hyperosmolar fluid into the bodies of very young children can cause problems of fluid balance)
- The elderly (for the same reason)
- Diabetics

- Patients with cardiac impairment
- Patients with renal impairment
- Asthmatics
- Patients who have previously reacted adversely to a contrast medium
- Patients with a history of allergy
- Patients who are unduly anxious

In total, these groups comprise approximately 25% of the patients referred for an IVU examination in a typical district general hospital. In addition, the guidelines propose that the low-osmolar media should be used in all painful arteriographic procedures. Not only does this reduce the discomfort that is usually associated with intra-arterial injections of high-osmolar contrast media, but also, because of the reduction in such discomfort, the patient is less likely to move during the exposures, so reducing the number of repeat radiographs required¹².

Comparative data on contrast media:

Having discussed in Section 5 the significance of the various properties that differentiate contrast media we are now in the position to compare the performances of several monomeric non-ionic contrast media in these areas.

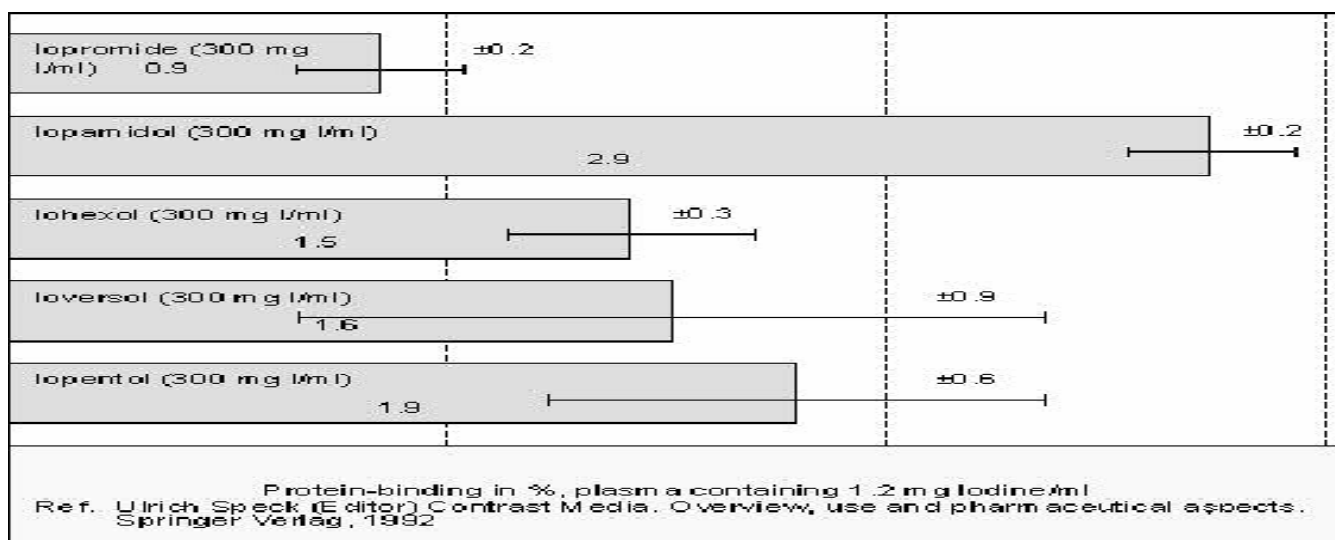


Fig. 2: Comparative protein-binding of monomeric non-ionic contrast media.

References:

1. Salvesen S. Acute toxicity tests of metrizamide *Acta Radiol.* 1973; 335 (Suppl.): 5-13.
2. Felder E, Pitre D, Tirone P. XLIV-Preclinical studies with a new nonionic contrast agent I *Farmaco* 1977; 32: 835-884.
3. Salvesen S, Acute intravenous toxicity of iohexol in the mouse and in the rat *Acta Radiol.* 1980; 362 (Suppl.): 73-75.
4. Mutzel W, Speck U. Tolerance and biochemical pharmacology of iopromide *Fortschr. Rontgenstr.* 1983; 118 (Suppl.): 11-17.
5. Ralston W H, Robbins M S, Coveney J, Blair M. Acute and subacute toxicity studies of ioversol in experimental animals *Invest. Radiol.* 1989; 24, (Suppl.) 2-9.
6. Michelet A, Salvesen S, Renaa T. Acute toxicity of iopentol in rodents *Acta Radiol.* 1987; 370 (Suppl.); 41-44.
7. Speck U, Mutzel W, Weinmann H-J. Chemistry, physiochemistry and pharmacology of known and new contrast media for angiography, urography and CT-enhancement *Fortschr, Rontgenstr.* 1983; 118 (Suppl.): 2-10
8. Katayama H, Yamaguchi K, Kozuka T, Takjashima T, Seez P, Matsuura K, Adverse reactions to ionic and non-ionic contrast media *Radiology* 1990; 175: 621-628
9. Grainger RG. The clinical and financial implications of the low osmolar radiological contrast media. *Clinical Radiology* 1984; 35: 251-252.
10. Grainger RG. Annotation: Radiological Contrast Media. *Clinical Radiology* 1987; 38: 3-5.
11. White RI Jr and Helen WJ Jr. Liquid Gold: low osmolality contrast media. *Acta Radiologica Diagnostica* 1986; 26: 457-461.
12. Grainger RG. Intravascular contrast media - The past, the present and the future. *British Journal of Radiology* 1982; 55: 1-18.

Author Information: Prof Dr Dhrubo Jyoti Sen is working as professor Department of Pharmaceutical and Medicinal Chemistry, Shri Sarvajanic Pharmacy College,

Article History:-----

Date of Submission: 22-02-10

Date of Acceptance: 28-03-10

Conflict of Interest: NIL

Source of support: NONE