

Protective effect of Chufa Tubers (*Cyperus esculentus*) on induction of sperm abnormalities In mice treated with lead acetate

Mahera N Al-Shaikh*; Tala. A. L. Abdul Wahab**; Sahar H Abdul Kareem**;
Salim R Hamoudi ***

* Prof. Dr. Head of Medical Biology, Department of Anatomy, Medical College, University of Baghdad

**Lecturer, Department of Basic Science, College of Dentistry, University of Baghdad

**** Prof. Dr. Head of Department of Pathology, Medical College, University of Baghdad

Abstract

The effect of the extract of *Cyperus esculentus* on the changes in sperm count, activity, morphology and testicular histology induced by lead acetate was studied. 18 adult male rats were randomly divided into three experimental groups. Group 1 (control) were given clean drinking water and rat chow, group 2 were given intraperitoneally injection 8mg/kg body weight + water + rat chow. Group 3 were given intraperitoneally injection 8mg/kg body weight + water with extract of *Cyperus esculentus* + rat chow. The results show a destruction in the testicular histology, decreased sperm count, activity and morphology of Group 2 administered with lead acetate only, which was statistically significant ($P < 0.05$), and there was also a dose-dependent improvement in the parameters studied in the Group 3 given extract of *Cyperus esculentus*. This shows that the extract of *Cyperus esculentus* has a regenerative effect on the destroyed testicular histology induced by lead acetate.

Key words:

Cyperus esculentus. Tests. Lead acetate

How to Cite this Paper:

Mahera N Al-Shaikh, Tala. A. L. Abdul Wahab, Sahar H Abdul Kareem, Salim R Hamoudi "Protective effect of Chufa Tubers (*Cyperus esculentus*) on induction of sperm abnormalities In mice treated with lead acetate" Int. J. Drug Dev. & Res., April-June 2013, 5(2): 387-392.

Copyright © 2013 IJDDR, Mahera N Al-Shaikh et al. This is an open access paper distributed under the copyright agreement with Serials Publication, which permits unrestricted use, distribution, and reproduction in any medium, provided the original work is properly cited.

Article History:-----

Date of Submission: 22-04-2013

Date of Acceptance: 30-05-2013

Conflict of Interest: NIL

Source of Support: NONE

INTRODUCTION

Lead is a heavy soft metal, occurs in nature as an oxide or salts. Due to the industrial processes and smokes from petrol vehicle (1) lead is considered as one of the major environmental pollutants and

*Corresponding author, Mailing address:
Mahera Noori Al-Shaikh
Iraq – Baghdad – College of Medicine –
Bab Al- Mouatham
Email: maheraalshaikh@yahoo.com

industrial pollution (2, 3). Lead acetate is used as water repellent for mildew protection and as a mordant for cotton dyes. Occupational lead exposure may occur during the manufacture of batteries, painting, printing, pottery glazing, and lead smelting processes. All sources of lead contribute to an increase in permissible exposure limit for metallic lead, lead oxide, and lead salts and soaps that has set by WHO and other health organizations (4).

Lead accumulates virtually in every tissue of the body and affects almost all the body systems specially RBCs, liver, nervous system, gonads and kidneys. Blood lead level is the most reliable indicator of lead intoxication. Neurotoxicity and cognitive loss is a well known side effect of lead even at low doses. The oxidative stress of lead causes damage to all components of the cell including cell membrane, proteins and nucleic acids (5).

Literature survey so far available indicates that lead treatment causes anemia (6). Testicular histochemical changes and spermatogenic inhibition have also been observed after lead administration in rats (7). The use of herbs in the treatment of different diseases is fast becoming revolutionized. In some countries, it has been integrated into the health scheme despite advances in orthodox medicine. It is believed that natural products if utilized in the correct form and dosage are less harmful than synthetic products, which most often elicit some anaphylactic response or reaction (8).

Cyperus esculentus

Cyperus esculentus (or chufa sedge, nut grass, yellow nutsedge, tigernut sedge, or earth almond) is a crop of the family (Cyperaceae) native to warm temperate to subtropical regions of the Northern Hemisphere. The tubers are edible, with a slightly sweet, nutty flavour, compared to the more bitter-tasting tuber of the related *Cyperus rotundus* (purple nutsedge). They are quite hard and are generally soaked in water before they can be eaten, thus making them much softer and giving them a better texture (9).

In ayurvedic medicine tigernuts are used in the treatment of flatulence, diarrhoea, dysentery, debility and indigestion.[10] Tigernut oil can be used in the cosmetic industry. As it is antioxidant (because of its high content in vitamin E) it helps slow down the ageing of the body cells. It favours the elasticity of the skin and reduces skin wrinkles.[11]. Therefore, this study is designed to confirm the effect of lead acetate on the histology of the testes and a possible testicular regenerative effect of *Cyperus esculentus* Extract.

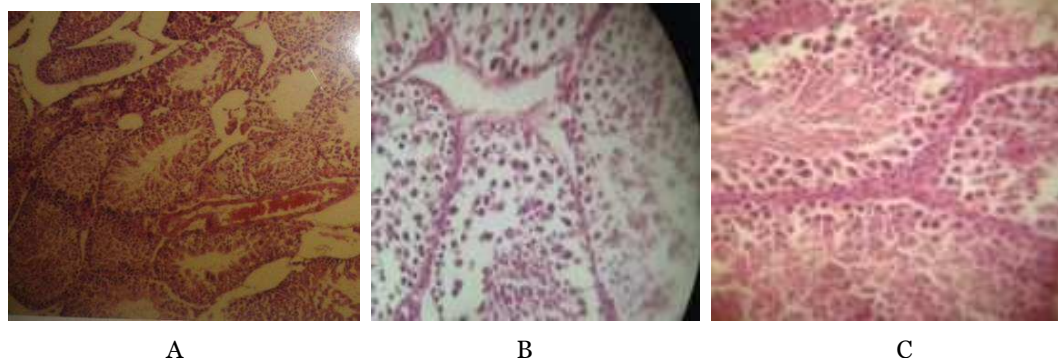
MATERIALS AND METHODS

The present study was conducted with 20 mature male albino mice, weighing about 25-35 gm was isolated in a relatively controlled environmental temperature of about 25 °C. in the animal breeding center / college of medicine / university of Baghdad. Food & drinking water were available *ad libitum*, 8 mg of Lead acetate (12) dissolved in 1 mL of distilled water was administered in a single intraperitoneal injection to adult mice. 18 animals divided into 3 groups: Group I control group received single intraperitoneally normal saline only. Group II received one injection intraperitoneally of lead acetate (8 mg) only, while group III received lead acetate and herbs extract of *Cyperus esculentus*. *Cyperus esculentus* seed were purchased from a local market in Syria. It was rinsed to remove sand and other debris. Soak two tablespoons of cyperus for the whole night in the water, then mashed and filtered (13), drinking with water for period of 4 weeks. Animals were killed on 15th and 30 days of treatment and the testes weighed, testes were dissected out for histopathological study.

The epididymes were excised and minced with fine scissors in physiological saline in a Petri dish. Smears were made on clean, grease free slides. The slides were air-dried and coded for subsequent examination under microscope for morphological abnormalities according to (14). Chambers of haemocytometer was charged with 5µl of the fluid, then the sperms were counted and the total numbers of sperms per mm³

were calculated. The data was expressed as Mean \pm SD. The differences between groups were compared for statistical significance by t-test with the level of significance set at $P \leq 0.05$.

Results



In contrast, in the lead acetate treated group, the tests showed an abnormal structure of the seminiferous tubules with vacuolar degenerative changes appearing in the cytoplasm of the spermatogenic epithelium and absence of late stage germ cells showed damage and sloughing of somniferous tubules (Fig. B). Testicular section from animal received lead acetate and treated with herbal extract showed a slight change from normal histological features, somniferous tubules with maturation of spermatogony and sperms inside the lumen (Fig. C).

Testicular weight and sperm count was significantly decreased in experimental groups compared with normal control group (table I).

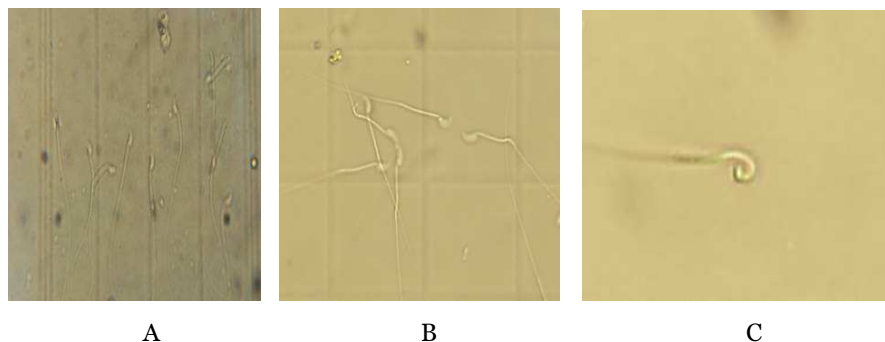
Light microscopy was used for evaluation of testicular histology and the seminiferous tubules of the control and different experimental groups shows: control group demonstrated normal somniferous tubules with presence of spermatogony maturation, spermatogenesis was evident in most tubules, and leydic cells are normal (fig. A).


Table 1: Changes in body weight and testicular sperm count

Groups	Testicular 2 week	Weight 4 weeks	sperm 2 week	Count 4weeks
Control	0.65 \pm 0.04	0.62 \pm 0.02	200 \pm 0.2	195 \pm 0.02*
Lead acetate	0.23 \pm 0.2*	0.3 \pm 0.4*	90 \pm 0.4*	100 \pm 0.2*
Lead acetate +herbal extract	0.52 \pm 0.2	0.45 \pm 0.2*	150 \pm 0.2*	140 \pm 0.2

P – Values * <0.05 compared with the corresponding vehicle treated controls.

The results of sperm head abnormality counts showed that there was a high level of abnormality in the sperm head of mice treated with lead acetate compared with control (A). These abnormalities observed are : hook at wrong angle (B) ,spiral head (C) , pin-head (D) , two tails (E) , head only (F) , sperm with no hook (F) , banana-shaped head (D) , amorphous head (D, H) , mean bent hook (G) .





DISCUSSION

Lead (Pb^{+2}) is a heavy metal that can be toxic when introduced into the human and animal bodies by ingestion or inhalation in sufficient quantities. It causes various destructive effects (15). In human, increased levels of lead causes many serious diseases and dysfunction of organs (16). Lead is well known to produce oxidative damage by enhancing lipid peroxidation (17) Lipid peroxidation inactivates cell constituents by oxidation or causes oxidative stress by undergoing radical chain reaction, ultimately leading to loss of membrane integrity (18). In analogy, lead was shown to implicate testicular lipid

peroxidation as evidenced by previous reports (19) this could be due to the formation of free radicals (18) through an exhaustion of antioxidants (20) and subsequently to oxidative stress (21).). On the other hand, since lead does not undergo oxidation-reduction cycle, the effect of lead on lipid peroxidation is not a direct effect, but these changes could rather be due to an indirect effect of lead on the free-radical scavenging enzymes(22) and/or glutathione peroxidase (20). However, the higher membrane lipid content of testes is presumed to make them more vulnerable to oxidative stress (23).

The elevation of frequency of sperm head abnormalities in mice treated with lead acetate may have caused damage to the pre-meiotic stages of spermatogenesis since during spermatogenesis, DNA synthesis occurs before pre-meiotic phase and no further DNA synthesis occurs throughout spermatogenesis in the cell cycle (24, 25). Several reasons have been put forward to explain the increase in the frequency of occurrence of sperm head abnormalities in organisms exposed to some chemicals. In general, damage to the sperm cell is said to occur either by physiological, cytotoxic or genetic mechanism. Odeigah (24) reported that exposure to the chemicals could produce pituitary hypothalamic or sex hormonal effects which in turn could affect spermatogenesis or exposure could cause abnormalities in seminal fluid resulting in functional or structural impairment of sperm. It may also arise as a consequence of naturally occurring level of mistakes in the spermatozoon differentiating process during spermatogenesis (26). In this study, Treated with *Cyperus esculentus* relatively improves the induced histopathological changes in the testis of rats caused by effect of lead acetate, these improvement may be either : directly on spermatogenesis by reducing lipid peroxidation and prevent or decrease the formation of free radicals , by acting as antioxidant . Or indirectly through pituitary hypothalamic or sex hormonal effects.

REFERENCES

- 1) Joworaski, Z. Stable and radioactive lead in environment and human body. Warsaw, Nuclear Energy Information Center, Review Report 1968; 29: 17-30.
- 2) Ghorbe, F., Boujelbene, M., Makni-Ayadi, F., Guermazi, F., Kammoum, A., Murat, Jc. Effect of chronic lead exposure on kidney function in male and female rats: determination of a lead exposure biomarker. Arch. Physiol. Biochem. 2001; 109: 457-463.
- 3) Patel, A.B., Williams, S.V., Frumkin, H., Kondawar, V.K., Glick, H., Ganju, A. K Blood lead in children and its determinants in Nagpur, India. Int. J. Occup. Environ. Health. 2001; 7: 119-26.
- 4) Harbison, RD. Lead. In: Harbison, R.D.(ed). Hamilton & Hardy's Industrial Toxicology, 5th ed, Mosby, Philadelphia. 1998, pp 70-76.
- 5) Farhan Ali*, Kusum Singh, Sapna Rani, Vinita Ahirwar and Shaista Khan .Protective effect of Vitamin C against lead acetate toxicity in blood glucose level of albino rats. IJPI'S Journal of Pharmacology and Toxicology 2011; 1, 2: ISSN 2229 – 6859.
- 6) Poulos L , Gammaz S. Statistically significant hematopoietic effects of low blood levels. Arch Environ Health 1986; 41:384 – 6.
- 7) Guloik ME, Spermatogenesis and maturation of spermatozoa in rats exposed to lead, Ann Acad Med Stetin, 1989; 35:73 –87.
- 8) OLATUNJI K. Health usefulness of vegetables. Health Monitor. 2005. 3 (4): 21.
- 9) Simpson D A and Inglis C A . Cyperaceae of economic , ethnobotanical and horticultural importance . Kew Bulletin .2001; 56: 257-360.
- 10) Abano, E.E. and K.K. Amoah, Effect of moisture content on the physical properties of tiger nut (*Cyperus esculentus*). Asian Journal of Agricultural Research 2011.. 5, 56-66
- 11) Tigernuts Traders, S.L., Tigernuts Oil, 2012, <http://www.tigernut.com> .
- 12) Biswas NM1 Ghosh P , Sahid Rameswar Vidyamandir . Effect of lead on male gonadal activity in Albino Rat. Kathmandu University Medical Journal .2004; 2(1):43-46
- 13) Charton E . Reduction and replacement of animal tests in the European Pharmacopoeia : recent developments for monographs on biological substances . Phamaaeuropa 1999; 11:197-199.
- 14) Wyrobeck AJ , Bruce WR. The induction of sperm shape abnormalities in mice and humans . In : Hollander A. de Serres FJ(ed). Chemicalmutagen , principles and methods for detection, ed 5 . Plenum Press, New York, 1978, 257-85.
- 15) Neathery MW, Miller WJ Metabolism and toxicity of cadmium, mercury, and lead in animals: a review. J. Dairy Sci .1975; 58(12): 1767-1781.

- 16) McGregor AJ, Mason HJ .Chronic occupational lead exposure and testicular endocrine function. Hum. Exp. Toxicol. 1990; 9(6): 371-376.
- 17) Ahmed EA, Mohamed AD and Saleh AQ. Protective role of flaxseed oil against lead acetate induced oxidative stress in testes of adult rats . African Journal of Biotechnology 2010; 9(42) : 7216-7223 .
- 18) Abdel-Wahhab MA, Aly SE . Antioxidant property of *Nigella sativa* (black cumin) and *Syzygium aromaticum* (clove) in rats during aflatoxicosis. J. Appl. Toxicol. 2005 ; 25(3): 218-223.
- 19) Acharya UR, Acharya S, Mishra M . Lead acetate induced cytotoxicity in male germinal cells of Swiss mice. Ind. Health .2003; 41(3):291-294.
- 20) Abdel-Wahhab MA, Omara EA, Abdel-Galil MM, Hassan NS, Nada SA,Saeed A, Elsayed M M . *Zizyphus spina-christi* extract protects against aflatoxin b(1)-intitiated hepatic carcinogenicity. Afr. J. Tradit.Complement Altern. Med.2007; 4(3): 248-256.
- 21) Shabani A, Rabbani A . Lead nitrate induced apoptosis in alveolar macrophages from rat lung. Toxicology,2000; 149(2-3): 109-114.
- 22) Jindal V, Gill KD. Ethanol potentiates lead-induced inhibition of rat brain antioxidant defense systems. Pharmacol. Toxicol. 1999 ; 85(1): 16-21.
- 23) Georgiou M, Perkins LM, Payne AH. Steroid synthesisdependent, oxygen-mediated damage of mitochondrial and microsomal cytochrome P-450 enzymes in rat Leydig cell cultures. Endocrinology, 1987 ; 121(4): 1390-1399.
- 24) Odeigah PGC .Sperm-head abnormalities and dominant lethal effects of formaldehyde in albino rats. Mutat Res . 1997 ; 389: 141-148.
- 25) Otubanjo OA, Mosuro AA . An in vivo evaluation of induction of abnormal sperm morphology by some anthelmintic drugs in mice. Mutat Res . 2001 ;497:131-138 .
- 26) Bakare AA, Mosuro AA, Osibanjo O. An in vivo evaluation of induction of abnormal sperm morphology in mice by landfill leachates. Mutat Res 2005; 582:28-34.

